

Gulf and Caribbean Research

Volume 6 | Issue 4

January 1980

Vertebral Anomaly in *Fundulus similis*

Charles S. Manning
Gulf Coast Research Laboratory

Follow this and additional works at: <https://aquila.usm.edu/gcr>



Part of the [Marine Biology Commons](#)

Recommended Citation

Manning, C. S. 1980. Vertebral Anomaly in *Fundulus similis*. Gulf Research Reports 6 (4): 429-429.
Retrieved from <https://aquila.usm.edu/gcr/vol6/iss4/13>
DOI: <https://doi.org/10.18785/grr.0604.13>

This Short Communication is brought to you for free and open access by The Aquila Digital Community. It has been accepted for inclusion in Gulf and Caribbean Research by an authorized editor of The Aquila Digital Community. For more information, please contact Joshua.Cromwell@usm.edu.

VERTEBRAL ANOMALY IN *FUNDULUS SIMILIS*

CHARLES S. MANNING

Microbiology Section, Gulf Coast Research Laboratory,
Ocean Springs, Mississippi 39564

ABSTRACT On May 11, 1978, a longnose killifish, *Fundulus similis*, exhibiting an extreme lordotic, scoliotic condition was collected on the north shore of Big Lagoon in Escambia County, Florida. The specimen was held for observation in a flow-through seawater aquarium for several weeks prior to being preserved and placed in the Gulf Breeze Environmental Research Laboratory Museum (No. AN-2146).

Vertebral anomalies have been reported in many fishes (Dawson 1964, 1966, 1971; Dawson and Heal 1976); however, I am unaware of any such reports for the longnose killifish *Fundulus similis* (Baird and Girard).

This specimen, standard length 54 mm (Figure 1), was collected on May 11, 1978, by Larry Goodman, James Patrick, Jim Eiland, and me in a 6.1 m beach seine on the north shore of Big Lagoon, approximately 1.1 km east of Trout Point, in Escambia County, Florida (salinity = 6 ppt, temperature = 28°C). Radiographs (Figure 1) taken shortly after capture show severe lordosis and scoliosis of the caudal vertebrae with a suggestion of abnormal rotation of the vertebrae on their longitudinal axis. The vertebral count revealed 14 thoracic and 20 caudal vertebrae.

The specimen was maintained with several similar sized longnose killifish in a flow-through seawater aquarium for observation for nine weeks. The extreme lordotic and scoliotic condition appeared to have little effect on the animal's ability to obtain food, maintain itself in the water column, or conduct itself "normally" under aquarium conditions. At the time of collection, and again four weeks after being placed in the aquarium, the specimen displayed male breeding coloration as described by Springer and Woodburn (1960). After nine weeks, the killifish developed fin rot and was preserved to avoid further degradation of tissues. The preserved specimen is now housed in the Gulf Breeze Environmental Research Laboratory Museum (No. AN-2146).

ACKNOWLEDGMENTS

I thank Lee Courtney for radiographs, Steve Foss for photographs, and Dr. John Couch for examination of the radiographs.

Manuscript received March 6, 1980; accepted March 17, 1980.

REFERENCES CITED

- Dawson, C.E. 1964. A bibliography of anomalies of fishes. *Gulf Res. Rept.* 1(6):308-399.
- _____. 1966. A bibliography of anomalies of fishes. Supplement 1. *Gulf Res. Rept.* 2(2):169-176.
- _____. 1971. A bibliography of anomalies of fishes. Supplement 2. *Gulf Res. Rept.* 3(2):215-239.
- _____. & Elizabeth Heal. 1976. A bibliography of anomalies of fishes. Supplement 3. *Gulf Res. Rept.* 5(2):35-41.
- Springer, V. G. & K. D. Woodburn. 1960. An ecological study of the fishes of the Tampa Bay area. *Fla. Board Conserv. Mar. Lab. Prof. Pap. Ser.*, No. 1, 104 pp.

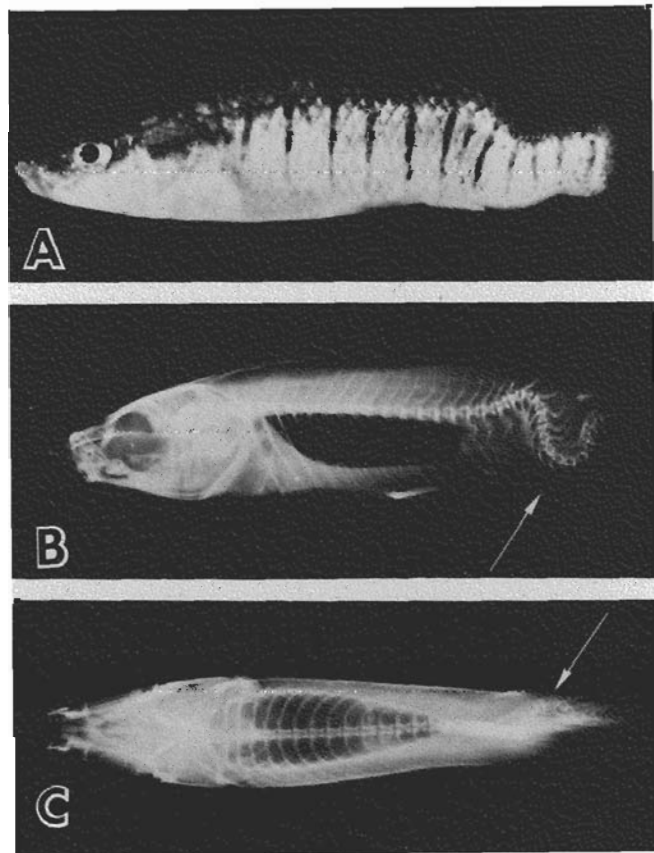


Figure 1. *Fundulus similis* from Escambia County, Florida. (A) Lateral view reveals anomalous morphology. (B) Radiograph reveals the extreme lordotic condition and slight rotation of vertebrae on their central axis. (C) Radiograph shows a lateral curvature (scoliosis) of the posterior caudal vertebrae (arrow).