

Gulf Research Reports

Volume 10 | Issue 1

January 1998

Occurrence of a Synchronous Hermaphroditic Striped Mullet, *Mugil cephalus*, from the Northern Gulf of Mexico

James S. Franks

Gulf Coast Research Laboratory, jim.franks@usm.edu

Nancy J. Brown-Peterson

Gulf Coast Research Laboratory, nancy.brown-peterson@usm.edu

Dyan P. Wilson

Gulf Coast Research Laboratory

Ronda J. Russell

Gulf Coast Research Laboratory

Janaith K. Welker

Gulf Coast Research Laboratory

DOI: 10.18785/grr.1001.04

Follow this and additional works at: <http://aquila.usm.edu/gcr>

 Part of the [Marine Biology Commons](#)

Recommended Citation

Franks, J. S., N. J. Brown-Peterson, D. P. Wilson, R. J. Russell and J. K. Welker. 1998. Occurrence of a Synchronous Hermaphroditic Striped Mullet, *Mugil cephalus*, from the Northern Gulf of Mexico. *Gulf Research Reports* 10 (1): 33-39.

Retrieved from <http://aquila.usm.edu/gcr/vol10/iss1/4>

This Article is brought to you for free and open access by The Aquila Digital Community. It has been accepted for inclusion in Gulf and Caribbean Research by an authorized editor of The Aquila Digital Community. For more information, please contact Joshua.Cromwell@usm.edu.

OCCURRENCE OF A SYNCHRONOUS HERMAPHRODITIC STRIPED MULLET, *MUGIL CEPHALUS*, FROM THE NORTHERN GULF OF MEXICO

James S. Franks, Nancy J. Brown-Peterson, Dyan P. Wilson, Ronda J. Russell
and Janaith K. Welker

GulfCoast Research Laboratory, Institute of Marine Sciences, University of Southern Mississippi
703 East Beach Drive, Ocean Springs, MS 39564, USA

Abstract A synchronous hermaphroditic striped mullet, *Mugil cephalus*, was captured offshore of Southwest Pass, Louisiana on 6 December 1996 during the commercial roe mullet fishery harvest. The fish measured 412 mm FL, weighed 824 g and was determined to be 4 years old by otolith analysis. Gross examination of the gonads revealed four lobes: right and left ovaries and right and left testis which represents a unique occurrence among hermaphroditic fish. All lobes ended in a common sperm duct/oviduct with the exception of the left ovary which had no oviduct. Both ovaries contained vitellogenic oocytes and both testis had freely running spermatozoa. Histological examination showed many oocytes undergoing final oocyte maturation, the presence of some post ovulatory follicles and lobules full of tailed spermatozoa. There was no evidence of the intermingling of sperm and oocytes within the gonad. The capture of this fish on the spawning grounds and the advanced stage of both ovarian and testicular development suggests spawning probably would involve the release of both oocytes and spermatozoa.

INTRODUCTION

Striped mullet, *Mugil cephalus*, are distributed worldwide in most coastal and estuarine waters of tropical and subtropical seas (Render et al. 1995). Striped mullet support an important commercial fishery in the Gulf of Mexico and the South Atlantic Bight where they are harvested for both their flesh and roe. The recent expansion of the striped mullet fishery in Alabama, Mississippi and Louisiana is directly related to the increased commercial harvest of seasonally available (October-January) "roe mullet" in the northern Gulf of Mexico (Leard et al. 1995).

The reproductive biology of striped mullet in the northern Gulf of Mexico has recently been documented (Render et al. 1995). Gonadal maturation of both males and females begins in the estuaries in September, while spawning occurs offshore from November through early January. Striped mullet are isochronal spawners, although batches of oocytes may be hydrated and spawned on successive days due to size limitations in the body cavity (Render et al. 1995). Chang et al. (1995) determined that striped mullet are an undifferentiated gonochorist species, with all individuals completing gonadal differentiation by 18 months.

Hermaphroditism is a relatively common reproductive strategy among teleosts and can be divided into three basic categories; protogyny, protandry and synchronous hermaphroditism (Sadovy and Shapiro 1987). Protogynous hermaphrodites function first reproductively as females and then change sex to become reproductively functioning males; protandrous hermaphrodites are first males and

then become sexually functioning females. Synchronous hermaphrodites are individuals that can function at the same time of life as both male and female.

In addition to normal hermaphroditism, in which all individuals within a species are hermaphroditic, there have been many reports of abnormal hermaphroditism (Atz 1964), in which hermaphroditic individuals of a normally gonochoristic species have been found. There have been several scattered reports of hermaphroditism in the Mugilidae, all based on one or two specimens. Ovotestes have been reported in *Mugil chelo* (Orlandi as cited in Moe 1966) and *M. platanus* (Andrade-Talmelli et al. 1994). Hermaphroditism in *M. cephalus* has been documented three times (Stenger 1959; Moe 1966; Thompson et al. 1991). The purpose of our report is to describe the occurrence of an unusual synchronous hermaphroditic striped mullet from the northern Gulf of Mexico, which differs substantially from previously described hermaphroditic mullet.

MATERIALS AND METHODS

A hermaphroditic striped mullet was captured on 6 December 1996 during commercial roe mullet harvesting operations conducted offshore of Southwest Pass, LA. The specimen was among thousands of mullet taken in a 16,000 kg pair-trawl haul that was iced on board the fishing vessel and subsequently transported to Clark Seafood Company, Pascagoula, MS for processing. The hermaphroditic specimen was detected on 9 December 1996 during routine roe mullet biological sampling conducted at the Clark facility and was one of 45 roe

mullet randomly selected and sampled on that date. Fork length (FL, mm) and total weight (TW, g) of all 45 mullet were recorded, and gonads were removed and weighed to the nearest 0.1 g.

The hermaphroditic specimen was brought to our laboratory for further examination and the gross morphology of the fresh gonads was described. We excised the gonads from the specimen but did not detach male from female elements. Gonads were measured for total length (mm) and greatest width (mm), blotted dry, weighed (total combined weight of ovaries and testes) and preserved whole in 10% neutral buffered formalin. The weight of the gonads was expressed as a function of total body weight by a gonadosomatic index (GSI) (DeVlaming et al. 1982):

$$\text{GSI} = (\text{gonad weight} / \text{total fish weight} - \text{gonad weight}) \times 100$$

We measured the diameter of ten of the most advanced stage oocytes (fresh) from the anterior and medial regions of the left and right ovaries as well as from the posterior region of the left ovary. Oocyte measurements were made to the nearest 0.001 mm using a binocular dissecting microscope with an image analysis system at 60x magnification. Mean diameter of leading stage oocytes was calculated for each region.

We estimated the specimen's age using sagittal otoliths, which were removed, cleaned with distilled water, and air dried. The left sagitta was embedded in Spurr (Secor et al. 1992) and sectioned through the core at 0.3-mm intervals along a transverse, dorso-ventral plane using a Buehler Isomet low-speed saw. Three sections were mounted on a microscope slide with CrystalBond 509 adhesive, sanded with wet 600- and 1500-grade sandpaper and polished on a felt wheel with 0.3 μ alumina micropolish. The opaque bands occurring from the otolith core to the outer margin were counted at 20-40x magnification using transmitted light.

Small (1 cm³) pieces of tissue were removed from the preserved ovarian and testicular tissues for histological analysis. Additionally, samples from areas where ovarian and testicular tissue appeared joined were taken. Tissue samples were dehydrated, cleared and embedded in paraffin following standard histological techniques. The tissues were sectioned at 5 μ m, mounted on slides and stained with hematoxylin and eosin prior to histological inspection. Oocyte, atretic and post ovulatory follicle (POF) stages were classified following Hunter and Macewicz (1985a, b).

RESULTS

An external inspection of the specimen indicated the fish was in good condition. The specimen measured 412 mm FL and weighed 834 g TW. The other specimens of

striped mullet (male, n = 32; female, n = 12) included in the random sample ranged from 289-468 mm FL (mean, 362 mm) and 300-1,372 g TW (mean, 626 g). The length of our specimen was greater than that of 81% of the males (mean, 258 mm) and 70% of the females (mean, 385 mm) in the sample, and its weight was greater than that of 88% of the males (mean, 588 g) and 58% of the females (mean, 794 g).

Internal observation revealed paired, well-developed ovaries and testes which occupied most of the body cavity (Figure 1). The bright yellow ovaries and the white testes appeared as distinctly individual organs, albeit uniquely juxtaposed within the body cavity. A generalized gross morphological description of the gonads follows.

Left ovary: The ovary measured 110 mm in length and 38 mm at its greatest width, approximately twice the greatest width of the right ovary. With the exception of the anterior-most portion, the entire left ovary was devoid of an ovarian wall (tunica albuginea; Figure 1) and appeared as a thick gelatinous mass of exposed, well-developed oocytes. The absence of an ovarian wall and the large egg mass gave the ovary a ruptured appearance. Only the anterior portion of the ovary with the tunica albuginea was attached to the dorsal wall of the fish. The remainder of the ovary was loosely adhered only to the left testis by mesenteries. The ovary ended abruptly 35 mm from the genital pore, and there was a conspicuous absence of an oviduct.

Right ovary: The ovary measured 135 mm in length and 22 mm in width at its anterior region. Approximately 50 mm from the anterior tip the ovary decreased in width to 10 mm and continued posteriorly as an ever-narrowing, bright yellow tube. The entire ovary was covered by tunica albuginea and was attached by mesenteries to the dorsal wall along its complete length. An oviduct extended to the region of the genital pore.

Left Testis: The testis measured 142 mm in length and 21 mm at its greatest width. The extremely narrow (4 mm) anterior region of the lobe was firmly attached to the left ovary (Figure 1). A small area of the ribbon-shaped anterior region located 20 mm from the anterior tip was so overlain with left ovarian tissue that the testis erroneously appeared to terminate at that point. The posterior-most 40 mm of the testis was attached to the dorsal wall, however, the remainder of the testis was attached by mesenteries to the left ovary only. A sperm duct extended to the region of the genital pore.

Right testis: The testis was neither as long (103 mm) nor as wide (14 mm at its greatest width) as the left testis. The organ was affixed to the dorsal wall (at attachment sites adjacent to those of the right ovary) along its entire length and was loosely joined by mesenteries to the mid-

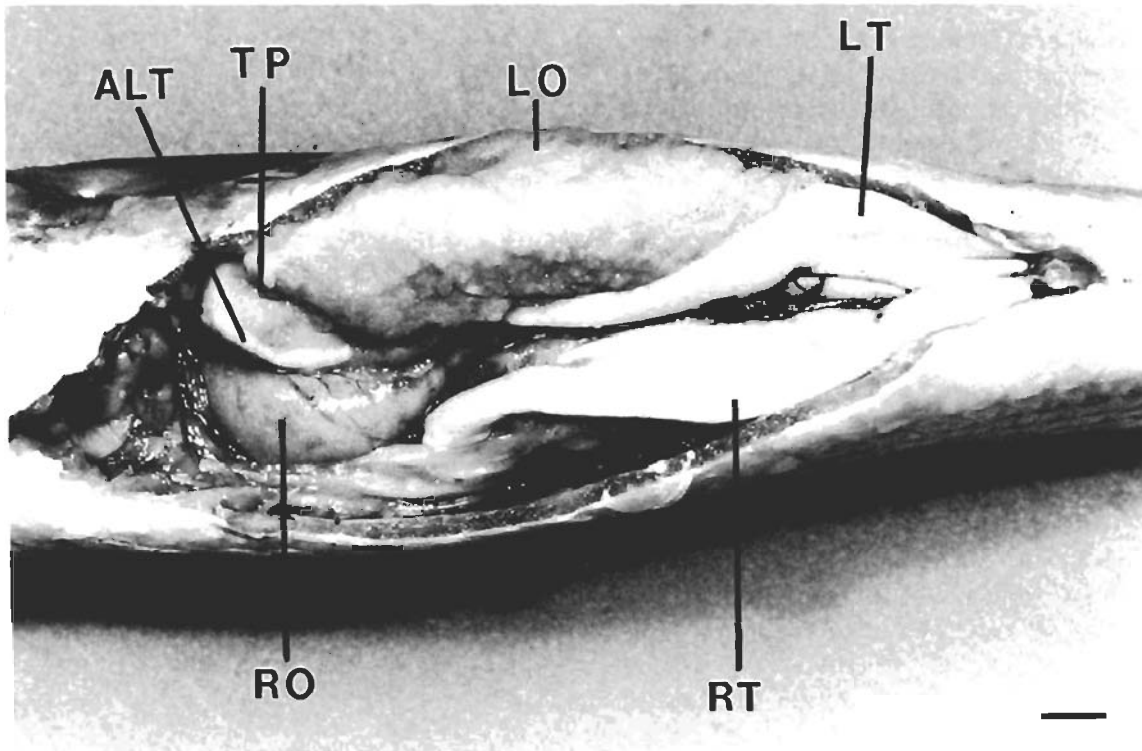


Figure 1. Paired gonads of the synchronous hermaphroditic striped mullet, *Mugil cephalus*. LO, left ovary; RO, right ovary; LT, left testis; RT, right testis; TP, termination point of tunica albuginea (ovarian wall) on left ovary; ALT, anterior region of left testis. Scale bar = 10 mm.

region of the right ovary. A sperm duct extended to the region of the genital pore.

Although the ovaries and testes were closely aligned within the body cavity, the gonads were well delineated and the germinal tissues were, in most instances, separated by mesenteries. There was no apparent intermingling of male and female tissues. The posterior region of each testis and the right ovary were loosely joined by mesenteries anterior to the genital pore. Each sperm duct and the right oviduct joined to form a common duct which terminated at the genital pore.

The total weight of the specimen's gonads (ovaries and testes) was 98.6 g, with a GSI value of 12.0. Mean GSI values for the 32 males and 12 females in the sample were $13.3 (\pm 0.75, \text{SEM})$ for males and $15.7 (\pm 1.89)$ for females, while mean GSI calculated for specimens similar in length (FL range, 394–419 mm) to the hermaphroditic fish were $9.8 (\pm 1.01)$ for males ($n = 7$) and $16.7 (\pm 4.19)$ for females ($n = 3$).

Each testis from the hermaphroditic specimen was sliced open and milt ran freely from the incisions. Observation of the fresh milt under a compound microscope revealed well-developed sperm. Macroscopic observations of the ovaries revealed that large, yolked oocytes in the migratory nucleus phase dominated the samples from all regions examined; the mean diameters of the leading stage

TABLE 1

Mean oocyte diameters (mm) from selected regions in the left and right ovary of a hermaphroditic striped mullet, *Mugil cephalus*.

Ovarian Region	Left Ovary	Right Ovary
Anterior	0.670	0.673
Medial	0.682	0.643
Posterior	0.642	Not Collected

oocytes are shown in Table 1. The posterior region of the left ovary also contained a substantial number of medium-size, yolked oocytes with a mean diameter of 0.334 mm.

Histological inspection of ovarian tissue from both the right and left lobes showed this specimen was an isochronal spawner undergoing final oocyte maturation, as evidenced by many oocytes in the migratory nucleus phase (Figure 2A). Some yolked oocytes from both lobes were in β -stage atresia (Figure 2A). Three 24-h post-ovulatory follicles (POF) were found in the anterior portion of the right ovary and two 24-h POF were found in the mid section of the right ovary; no other ovarian sections showed evidence of recent spawning.

Histological inspection of testicular tissue from both the right and left lobes showed lobules full of spermatozoa as well as spermatozoa in the sperm ducts (Figure 2B). Late stages of spermatogenic activity (secondary spermatocytes and spermatids) occurred in cysts in the periphery of the testis. The testicular walls appeared unusually thick in this specimen, although there was no evidence of abnormal morphology or cellular structure.

Tissue samples taken from areas where ovarian and testicular tissues overlapped showed thick testicular walls, no interconnections between the ovaries and testis and no intermixing of sperm and oocytes (Figure 2C). Areas where ovaries and testes appeared upon gross examination to be fused separated into distinct ovarian and testicular tissues after histological processing; no evidence of tearing or destruction of the testicular wall was apparent.

Otolith analysis revealed three distinctive opaque bands with considerable growth of the otolith beyond the last band. Based on age validation of striped mullet from Louisiana (Thompson et al. 1989) and time of first annulus formation (Thompson et al. 1991), we estimate an age of four years for the specimen.

DISCUSSION

The occurrence of fully developed ovaries and testes and histological evidence that spawning was eminent (final oocyte maturation and spermatozoa in the sperm duct) leads us to conclude that this mullet is a synchronous hermaphrodite, although with several notable differences from normal synchronous hermaphrodites. Sadovy and Shapiro (1987) state that all normal synchronous hermaphrodites have an undelimited gonad, meaning there is no membrane or connective tissue separating the male and female structures. Thus, two gonadal lobes, each containing testicular and ovarian tissues, is the norm with synchronous hermaphrodites. In no cases are normal synchronous hermaphrodites reported to have four lobes of gonadal tissue.

The specimen we examined is also unique among abnormal hermaphrodites. The majority of hermaphroditic individuals of gonochoristic species have ovotestes (Atz 1964) or occasionally ovaries and an ovotestis (Pinto 1952; Holliday 1962 as cited in Atz 1964), and many have been reported to contain mature oocytes and spermatozoa simultaneously. Of the five previously published cases of hermaphroditism in mullets (Stenger 1959; Moe 1966; Orlandi as cited in Moe 1966; Thompson et al. 1991; Andrade-Talmelli et al. 1994), all involved a one or two lobed ovotestis. Moe (1966) and Orlandi (as cited in Moe 1966) observed the gonads of three mullet that were

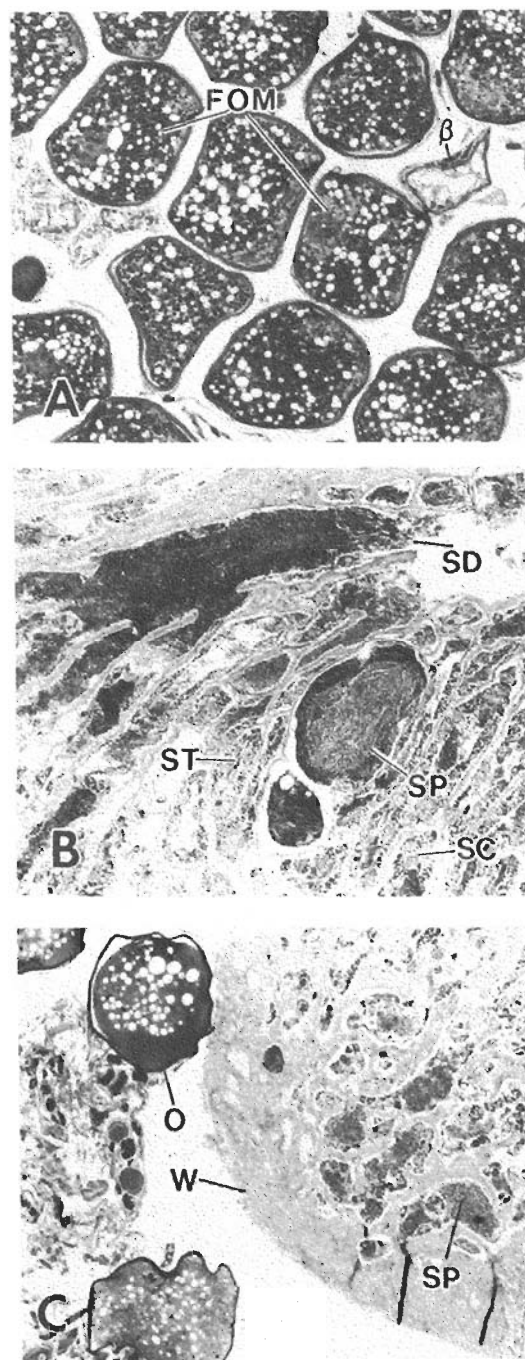


Figure 2. Histological sections from the gonads of the hermaphroditic striped mullet, *Mugil cephalus*. A. Section from the left ovary showing isochronal oocyte development with some oocytes undergoing final oocyte maturation (FOM). β , yolked oocyte in β -stage atresia. 66X. B. Section from the left testis in late stages of spermatogenesis showing secondary spermatocytes (SC), spermatids (ST) lobules full of spermatozoa (SP) and spermatozoa in the sperm duct (SD). 64X. C. Section showing separation of left ovarian and testicular tissue at the anterior end which appeared to be fused upon gross observation. Note the thick testicular wall (W) and that there is no intermingling of oocytes (O) and spermatozoa (SP). 66X.

primarily ovarian in nature, but contained patches of testicular tissue. Histological examination of one *M. cephalus* ovotestis revealed mesenteries separating the ovarian and testicular tissues and simultaneous development of both oocytes and sperm (Moe 1966). Stenger (1959) reported a *M. cephalus* gonad that appeared ovarian on gross examination, but contained a section with tailed spermatozoa upon histological inspection. The gonads of two hermaphroditic specimens of *M. platanus* appeared to be predominately testicular with small patches of ovarian tissue (Andrade-Talmelli et al. 1994). In one of those specimens, the ovarian and testicular tissues were separated by mesenteries and in the other, mature oocytes and tailed spermatozoa were freely mixing within the gonad. Most recently, Thompson et al. (1991) reported a four-year-old *M. cephalus* with two gonadal lobes containing a mosaic of ovarian and testicular tissues in an advanced stage of reproductive development. Finally, an unpublished report of a hermaphroditic *M. cephalus* captured from the Neuse River, NC in October 1982 described a two lobed gonad, predominately testicular, with large patches of ovarian tissue containing yolked oocytes on the anterior portion of each testis (S. W. Ross, North Carolina National Estuarine Research Reserve, Wilmington, NC, pers. comm.). In no previously cited cases have distinctively separate ovarian and testicular gonads been reported in a hermaphroditic mullet.

Hermaphroditic striped mullet are rarely encountered in the northern Gulf of Mexico. A major processor of roe mullet in the northern Gulf of Mexico could not remember a single instance of hermaphroditism in striped mullet during his many years of processing thousands of mullet for the roe market, nor could he recall that other mullet processors within the region had ever mentioned such an occurrence to him (Mr. Phil Horn, Clark Seafood Company, Pascagoula, MS, pers. comm.). We agree that such an occurrence is rare, since it is unlikely that the distinctively unique condition would go unnoticed (or unreported) by seafood plant employees engaged in the processing of roe mullet. Furthermore, fisheries personnel with the Gulf Coast Research Laboratory doing routine biological sampling have never encountered a striped mullet exhibiting hermaphroditic characteristics. Reported occurrences of hermaphroditic *M. cephalus* from the Gulf of Mexico are rare in the published literature. Stenger (1959) described one specimen from Florida waters and Thompson et al. (1991) discussed one specimen caught nearshore in Mississippi. Moe (1966) reported on two specimens from the Gulf waters off Florida which commercial fishermen had saved as a curiosity, suggesting the rarity of the occurrences. Additionally, Moe (1966) commented that no

other incidents of hermaphroditism in striped mullet from Florida could be documented despite extensive dialogue with biologists and fish dealers. Hermaphroditic striped mullet are also rare in the South Atlantic Bight; no cases have been reported in the literature although one specimen was captured in the Neuse River, NC (S.W. Ross, pers. comm.).

The abnormal hermaphroditic condition of our specimen did not appear to affect its growth. The age of the hermaphroditic fish (4 years) agreed favorably with the ages (3-5 years) of ten other striped mullet from the random sample which were similar in size to the study specimen. Additionally, our specimen was only slightly longer than the mean fork lengths reported for Louisiana striped mullet with three and four annuli on their otoliths (Thompson et al. 1989).

The GSI value of our hermaphroditic specimen was similar to GSIs of the normal, gonochoristic striped mullet collected in the same sample. Additionally, the GSI value of our specimen (12.0) was similar to the GSI of the North Carolina hermaphroditic striped mullet (12.9; S.W. Ross, pers. comm.). However, Render et al. (1995) reported a GSI value for Louisiana females captured in November and December of approximately 23.0 for the mean length interval of 410-420 mm FL, a value considerably larger than that for our specimen; GSI values were not reported for males larger than 380 mm. While striped mullet GSI values can vary in the same month among years (Render et al. 1995), we feel the discrepancy in GSI values between the Louisiana and Mississippi fish is related to differences in location of capture. The Louisiana striped mullet were captured in estuarine/coastal areas at the start of their spawning migration (Render et al. 1995), while our specimen was captured offshore on the spawning grounds. Render et al. (1995) reported no histological evidence of final oocyte maturation (FOM) or POF in the striped mullet they examined, suggesting spawning had not yet commenced, resulting in maximal GSI values. The striped mullet that we examined was in a more advanced stage of ovarian development than any examined by Render et al. (1995), as evidenced by the large numbers of oocytes undergoing FOM. Additionally, the presence of β -stage atresia, unreported by Render et al. (1995) in developing ovaries, suggests some fully mature oocytes had not undergone hydration and spawning. Finally, the presence of POF in the right ovary of our hermaphroditic striped mullet suggests spawning in the previous 24 hours, which would result in a reduction of GSI.

Although oocyte development in our specimen appeared to be progressing normally in both ovaries and was in the FOM stage, eggs could not have been released in a normal

fashion from the left ovary due to the lack of an oviduct. Histological evidence of recent oocyte hydration and spawning in this specimen (i.e., POF) may explain the ruptured appearance of the left ovary; perhaps the dramatic increase in ovarian mass during hydration and the inability to release the oocytes through an oviduct resulted in the rupture of the tunica albuginea. It is unknown if this fish would have survived the spawning season with a ruptured left ovary. However, the size and age of the fish suggests this was not its first spawning season (Render et al. 1995; Leard et al. 1995; Thompson et al. 1991), raising questions regarding gonadal condition and maturity in the previous year.

Although the occurrence of abnormal hermaphroditism has been documented in a variety of species (Atz 1964), there has never been a satisfactory answer to how this unusual situation develops. The recent interest in endocrine disrupters, as well as the experimental induction of ovotestes in the medaka (*Oryzias latipes*) following exposure to 4-nonylphenol (Gray and Metcalfe 1997), suggests that environmental exposures to estrogenic compounds may explain some reported cases of hermaphroditism. However, the endocrine disrupter explanation would only apply to abnormal hermaphrodites with ovotestes, which is clearly not the case for the striped mullet reported here. Given the rarity of the type of hermaphroditism reported here, we can only conclude that this fish received "mixed messages"

during gonadal differentiation, resulting in the development and eventual maturation of separate ovaries and testes.

ACKNOWLEDGEMENTS

Several people from the Gulf Coast Research Laboratory (GCRL) contributed to this study. Susan Carranza and William E. Hawkins took photographs of the specimen and histological slides, respectively, and Susan Carranza did the darkroom work to provide the final prints. Amber Garber and Robert Allen assisted with the histological preparations and staining and James Warren provided verification on the age of the specimen. Michael Moxey assisted in the routine sampling of roe mullet. We thank Doug and Phil Horn of Clark Seafood Company, Pascagoula, MS for their cooperation in allowing us the opportunity to sample roe mullet at their seafood plant. We also thank Steve W. Ross, North Carolina National Estuarine Research Reserve, Wilmington, NC for sharing his unpublished information on a hermaphroditic mullet. We appreciated the constructive comments from two anonymous reviewers. This work was supported in part by funding provided by The Mississippi Department of Marine Resources, Biloxi, MS (Mississippi Tidelands Trust Fund grant to GCRL, James Warren principle investigator) and the Institute of Marine Sciences, Gulf Coast Research Laboratory, Ocean Springs, MS.

LITERATURE CITED

- Andrade-Talmelli, E.F., E. Romagosa, M. Y. Narahara and H.M. Godinho. 1994. Ocorrência de hermaphroditismo em tainha *Mugil platanus* (Pisces, Mugilidae) na região estuarino-lagunar de Cananeia, SP, Brasil. *Boletim de Instituto de Pesca* 21:111-116.
- Atz, J.W. 1964. Intersexuality in Fishes. In C.N. Armstrong and A.J. Marshall, eds., *Intersexuality in Vertebrates Including Man*. Academic Press, New York, NY, USA, p 145-232.
- Chang, C-F., S-C. Lin and H-Y. Chou. 1995. Gonadal histology and plasma sex steroids during sex differentiation in grey mullet, *Mugil cephalus*. *The Journal of Experimental Zoology* 272:395-406.
- De Vlaming, V., G. Grossman and F. Chapman. 1982. On the use of the gonosomatic index. *Comparative Biochemistry and Physiology* 73A:31-39.
- Gray, M.A. and C.D. Metcalfe. 1997. Induction of testis-ova in Japanese medaka (*Oryzias latipes*) exposed to *p*-nonylphenol. *Environmental Toxicology and Chemistry* 16:1082-1086.
- Hunter, J.R. and B.J. Macewicz. 1985a. Measurement of spawning frequency in multiple spawning fishes. In R. Lasker, ed., *An Egg Production Method for Estimating Spawning Biomass of pelagic fish: Application to the Northern Anchovy (*Engraulis mordax*)*, NOAA Technical Report NMFS 36, United States Department of Commerce, Washington, D.C., USA, p 79-94.
- Hunter, J.R. and B.J. Macewicz. 1985b. Rates of atresia in the ovary of captive and wild northern anchovy, *Engraulis mordax*. *Fishery Bulletin*, U.S. 83:119-136.
- Leard, R., B. Mahmoudi, H. Blanchet, H. Lazuski, K. Spiller, M. Buchanan, C. Dyer and W. Keithly. 1995. The striped mullet fishery of the Gulf of Mexico, United States: a regional management plan. *Gulf States Marine Fisheries Commission*, Ocean Springs, MS, USA., No. 33.
- Moe, M.A. Jr. 1966. Hermaphroditism in mullet, *Mugil cephalus* Linnaeus. *Quarterly Journal of the Florida Academy of Sciences* 29:111-116.
- Render, J.H., B.A. Thompson and R.L. Allen. 1995. Reproductive development of striped mullet in Louisiana estuarine waters with notes on the applicability of reproductive assessment methods for isochronal species. *Transactions of the American Fisheries Society* 124:26-36.
- Sadovy, Y. and D.Y. Shapiro. 1987. Criteria for the diagnosis of hermaphroditism in fishes. *Copeia* 1987:136-156.
- Secor, D.H., J.M. Dean and E.H. Laban. 1992. Otolith removal and preparation for microstructural examination. In D.K. Stevenson and S. E. Campana (eds.), *Otolith Microstructure Examination and Analysis*. p 19-57. *Canadian Special Publications on Fisheries and Aquatic Sciences* p 19-57.

HERMAPHRODITIC STRIPED MULLET

- Stenger, A.H. 1959. A study of the structure and development of certain reproductive tissues of *Mugil cephalus* Linnaeus. *Zoologica: New York Zoological Society* 44:53-78.
- Thompson, B.A., J.H. Render, R.L. Allen, and D.L. Nieland. 1989. Life history and population dynamics of commercially harvested striped mullet, *Mugil cephalus*, in Louisiana. Final report to the Louisiana Board of Regents. Coastal Fisheries Institute, Louisiana State University, Baton Rouge, LA., USA. LSU-CFI-89-01. 80 p.
- Thompson, B.A., J.H. Render, R.L. Allen and D.L. Nieland. 1991. Fishery independent characterization of population dynamics and life history of striped mullet in Louisiana. Final Report of Cooperative Agreement NA90AA-H-MF-113, Coastal Fisheries Institute, Louisiana State University, Baton Rouge, LA, USA.